

PREDICTION OF DEVELOPMENT OF CHRONIC RHINOSINUSITIS WITH NASAL POLYPS IN CHILDREN TAKING INTO ACCOUNT THE GEOMETRIC CHARACTERISTICS OF THE ETHMOID LABYRINTH

Durdona D. Alimova¹, Aminjon Sh. Amonov²

1 Department of Otorhinolaryngology, Pediatric Otorhinolaryngology, Pediatric Dentistry, Tashkent Pediatric Medical Institute, Tashkent, Uzbekistan
E-mail: dr.alimova@mail.ru

2 Department of Otorhinolaryngology, Pediatric Otorhinolaryngology, Pediatric Dentistry, Tashkent Pediatric Medical Institute, Tashkent, Uzbekistan

ABSTRACT

This article presents the results of forecasting and early diagnosis of CRSwNP based on studying the features of the structure of the ethmoidal cells in children using CT imaging. Area indicators of the ethmoidal cells below 41.32 sm² are diagnostic criteria for assigning a child to the at-risk group for developing nasal polyps, while values below 28.5 sm² allow for diagnosing CRSwNP in children.

Key words: chronic rhinosinusitis, nasal polyps, diagnosis, ethmoidal cells.

INTRODUCTION

Chronic Rhinosinusitis with Nasal Polyps (CRSwNP) is a chronic inflammatory disease of the nasal cavity mucosa and paranasal sinuses, characterized by the formation and recurrent growth of polyps, consisting mainly of edematous tissue infiltrated with cellular elements: eosinophils, neutrophils [4, 8].

Although CRS with nasal polyps itself is not considered a severe condition, its symptoms – nasal congestion, rhinorrhea, sneezing attacks, and nasal itching – have a negative impact on the social, physical, and mental aspects of a person's life [1, 3, 10].

This article presents the results of assessing the effectiveness of diagnosis and treatment of CRS with nasal polyps by using information on the geometric characteristics of the ethmoidal labyrinth structure.

The choice of the ethmoidal labyrinth is not random. On the one hand, due to its anatomical position, the ethmoidal labyrinth cannot but have an influence on the ostiomeatal complex and, therefore, affect mucociliary clearance and transport [5]. On the other hand, there is very little attention given to the study of the ethmoidal labyrinth. In the available scientific literature and scientific periodicals, there are only occasional reports on the peculiarities of the anatomical structure of the ethmoidal labyrinth cells. Almost all studies on CRSwNP mention a disruption of mucociliary clearance in the nasal cavity [7, 9], but there is little information on what disruptions occur in the cells of the ethmoidal labyrinth.

Despite the level of theoretical and practical knowledge, many aspects of the etiology, pathogenesis, and, therefore, rational treatment tactics of CRSwNP remain not fully understood [2, 6].

Fundamental studies on the physiology and pathophysiology of the nose and paranasal sinuses have demonstrated the leading role of the lateral wall of the nasal cavity in the development of pathological processes in the paranasal sinuses [5, 8, 9]. Since abnormal structure of the lateral wall of the nasal cavity contributes to the onset and spread of pathological processes in the paranasal sinuses, the geometric characteristics of the structural anomaly can serve not only as a quantitative measure of the anomaly but also as a measure of the development of the pathological process and, therefore, can be used in the diagnosis and treatment of the pathological process.

Research objective: to predict and early diagnose CRSwNP based on studying the peculiarities of the ethmoidal labyrinth structure in children.

Material and methods of the study.

The geometric characteristics of the ethmoidal labyrinth were studied on CT images and their relationship with CRSwNP was examined. The study involved 142 children with various nasal cavity and paranasal sinus pathologies.

All children underwent a general clinical examination, including: general blood analysis, general urine analysis, anterior and posterior rhinoscopy, endoscopic rhinoscopy, and computed tomography. Based on the data from this examination, the patients were divided into three groups:

1. The group of conditionally healthy children included 30 children who were admitted to the ENT department with suspicion of nasal cavity and paranasal sinus diseases. Examination did not reveal any structural disorders of the ostiomeatal complex or any nasal disorders in them.

2. The group of patients with morpho-anatomical features of the ostiomeatal complex, conditionally called prone to developing nasal polyps (PDNP), included 32 children. These patients had the following ostiomeatal complex disorders: deviation of the uncinate process (13), deviation of the nasal septum in the cartilaginous part (13), concha bullosa (3), hypertrophy of the ethmoid bulla (4), crest or spur in the posterior parts of the nasal septum (12), hypertrophy of the posterior ends of the inferior nasal concha (12).

3. A group of patients with CRSwNP consisted of 80 children. This group included patients with recurrent CRSwNP (22 children) and polyposis-purulent form (58). During rhinoscopy, polypous overgrowths were observed in the middle or upper nasal passages. According to CT data, polyps filled the entire volume of the ethmoidal cells, the walls between the septa were thin, and there was thickening of the mucous membrane in the maxillary sinuses. The frontal and sphenoid sinuses were clear.

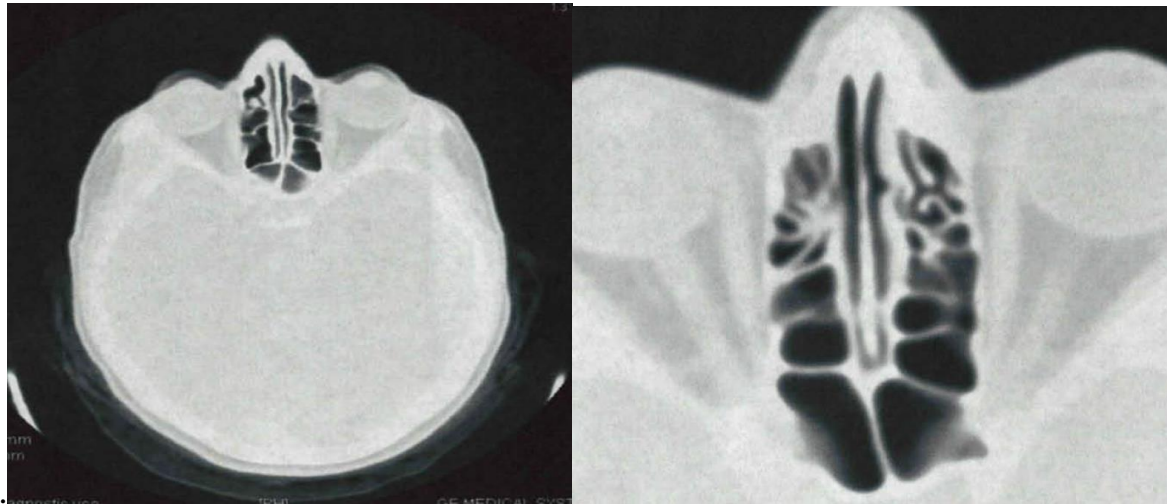
Endoscopic examination revealed deviation of the nasal septum to one side (31), signs of chronic sinusitis (21), vasomotor rhinitis (9), chronic hypertrophic rhinitis (19), as well as changes in the osteomeatal complex: deviation of the uncinate process - 30, concha bullosa - 28, hypertrophy of the ethmoidal bulla - 22, deviation of the nasal septum in the anterior and posterior parts - 54, hypertrophy of the posterior ends of the inferior nasal turbinate - 33 children.

Children from the last two groups complained of difficulty breathing through the nose, mucous or mucopurulent nasal discharge, and hyposmia.

The areas of the ethmoidal cells were calculated on CT images for all patients, by cell groups and overall. The study of the entire set of images obtained from computer tomography allowed us to hypothesize a connection between the size of the ethmoidal cells and CRSwNP.

Research results.

CT images of the ethmoidal cells in conditionally healthy children and patients with CRSwNP showed significant differences in the sizes of the ethmoidal cells, with the sizes of the ethmoidal cells in patients predisposed to CRSwNP being smaller than in conditionally healthy patients, but larger than in patients with CRSwNP (Pic.1).



Pic. 1. Tomogram of patient A., 15 years old. Cells of the ethmoid labyrinth

The differences were particularly noticeable in the axial projection. Since CT images are two-dimensional objects, the area was naturally chosen as a measure of the spatial dimensions of the ethmoidal cells.

Table 1 shows the values of the sample mean, sample standard deviation of the total area of the ethmoidal cells, and the area of the cell group for the three groups of patients under consideration.

As can be seen from the presented data, in the examined children with CRSwNP, the mean value of the total area significantly decreased compared to conditionally healthy children ($P < 0.01$). In children prone to developing nasal polyps, these indicators tend to decrease compared to the group of conditionally healthy children and differ by a factor of 1.3, and by a factor of 1.7 compared to children with CRSwNP. The average area of the anterior cells in CRSwNP decreased by 2.2 times compared to the indicators of conditionally healthy children and by 1.8 times compared to children predisposed to CRSwNP.

Table 1
Indicators of the ethmoid labyrinth cell area among examined children

Sample	Conditionally healthy children, n=30	Children prone to developing nasal polyps, n=32	Children with CRSwNP, n=80
Total area, sm^2	46,332±2,86	36,514±2,69*	21,941±2,50*^
Area of anterior cells, sm^2	30,115±2,20	23,874±2,51*	13,402±1,94*^
Area of posterior cells, sm^2	16,217±1,65	12,640±1,91*	8,539±1,61*^

Note: * - significance of data compared to indicators of conditionally healthy children ($P < 0.05$); ^ - significance of data compared to indicators of children prone to developing nasal polyps ($P < 0.05$).

Independence of the cell sizes of the ethmoid labyrinth from the gender and age of patients is demonstrated by the data presented in Table 2.

As can be seen from the table, characteristic changes in indicators depend only on the corresponding group of children.

The obtained data allow calculating the ranges of distribution of changes in the area of the grid substance to predict the development of CRSwNP in children.

For children in the conditionally healthy group, the area of the ethmoid labyrinth is within $45.38 \pm 2.31 - 47.43 \pm 3.90$, for PDNP – $35.52 \pm 2.24 - 37.58 \pm 3.61$, and for children with CRSwNP – $20.42 \pm 2.27 - 21.53 \pm 3.65$.

According to the data presented in Table 1, values and the position of boundaries between the sets of values of the area of the ethmoid cells corresponding to different groups of patients can be calculated. The boundary between CRSwNP and PDNP approximately healthy corresponds to $k = 2.981$, $S_k = 28.5 \text{ sm}^2$, PDNP ~ conditionally healthy - $k = 1.748$, $S_k = 41.32 \text{ sm}^2$.

Table 2

Minimum and maximum values of the area of the ethmoid labyrinth cells among examined children

Groups	Age, years				Gender	
	5-8	9-11	12-15	>15	Boys	Girls
Conditionally healthy children, n=30	$\frac{43,861}{50,151}$	$\frac{41,161}{50,651}$	$\frac{42,621}{51,261}$	$\frac{42,032}{49,531}$	$\frac{41,161}{50,742}$	$\frac{42,122}{51,263}$
Children prone to developing nasal polyps, n=32	$\frac{32,382}{40,329}$	$\frac{33,212}{40,860}$	$\frac{32,571}{37,012}$	$\frac{34,262}{35,734}$	$\frac{30,301}{41,023}$	$\frac{32,384}{40,331}$
Children with CRSwNP, n=80	$\frac{18,487}{23,842}$	$\frac{18,371}{25,021}$	$\frac{12,359}{25,574}$	$\frac{17,572}{26,033}$	$\frac{15,893}{25,673}$	$\frac{12,354}{26,032}$

Note: numerator - minimum number; denominator - maximum number

Belonging to a particular group of children depends on the position of the ethmoid labyrinth cells area value S of a particular patient relative to the obtained boundary values S_k . A patient belongs to the CRSwNP group if $S < 28.5$, to the PDNP group if $28.5 < S < 41.32$, and to the conditionally healthy group if $S > 41.32$. (Fig. 2).

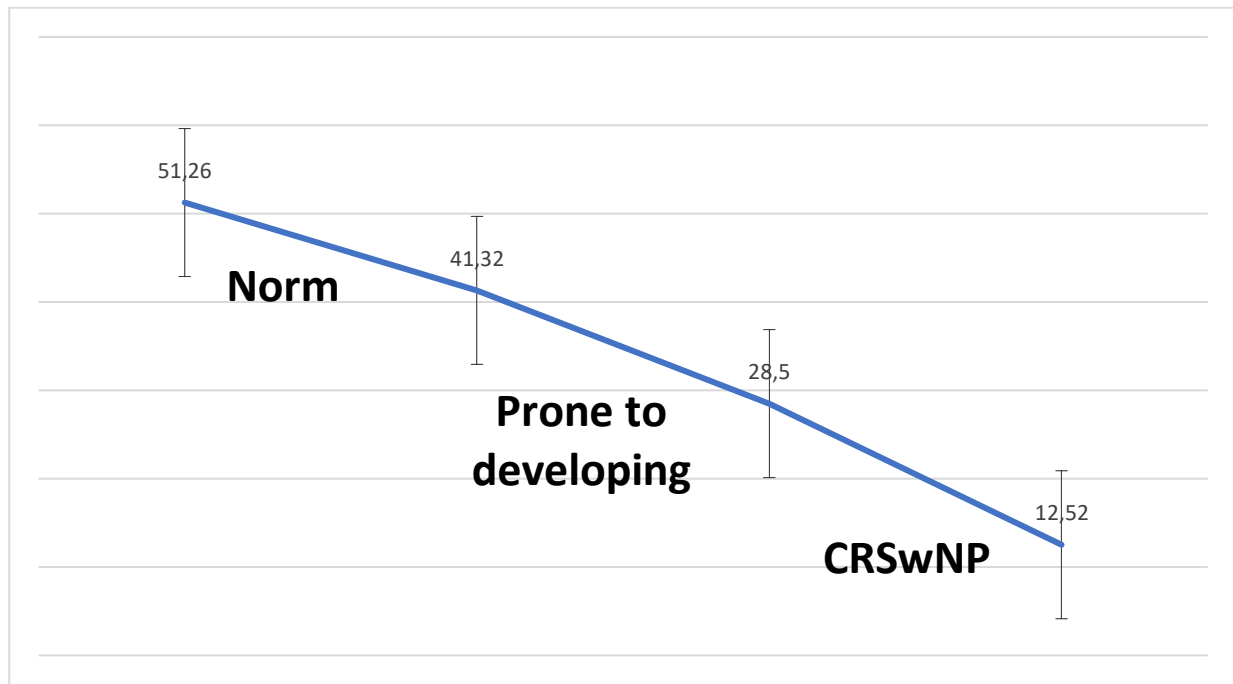


Fig. 2. Threshold values of the ethmoid labyrinth area in children

During the analysis of data obtained when applying the proposed boundary values of the ethmoid labyrinth cell area among examined children in the dynamics of our diagnosis, it was confirmed that out of 112 children with signs of CRSwNP, the diagnosis was not confirmed in 32 cases, while CRSwNP was established in 80 cases.

Among the 32 children, the area indicators of the grid labyrinth were within 28.5-41.32 cm² in 93.7% (30 out of 32 children), and in 6.25% of cases (2 out of 32 children), they were within the normative values (>41.32 cm²).

In the group with CRSwNP out of 80 children, 76 (95.0%) had area indicators of the ethmoid labyrinth below 28.5 cm², while 4 children had values above 28.5 cm², i.e. corresponding to PDNP. However, it should be noted that their values did not exceed 30 cm².

As a result, true positive results were obtained in 76 cases, false positive in 2 cases, true negative in 30 cases, and false negative in 4 cases.

According to the obtained data, the diagnostic value was 93.7%, diagnostic sensitivity was 95.0%, and diagnostic efficiency was 94.4%.

Thus, based on the calculation of the total area of the grid labyrinth, the development of CRSwNP in children can be predicted. If the indicators are below 41.32 cm², such children should be classified as at risk and be placed under dynamic observation every 6 months with a follow-up CT scan once a year.

Conclusions.

1. Conducting a CT study with the calculation of the ethmoid labyrinth area provides an opportunity to predict the development of nasal polyps in children.
2. Area indicators of the ethmoid labyrinth below 41.32 sm² are diagnostic criteria for categorizing a child at risk for developing CRSwNP, while values below 28.5 sm² allow diagnosing CRSwNP in them.
3. According to the obtained data, the diagnostic specificity of calculating the ethmoid labyrinth area on CT was 93.7%, sensitivity was 95.0%, and diagnostic efficiency was 94.4%.

REFERENCES

1. Abdumadjidovich A. A. et al. The effectiveness of endoscopic sinus-surgery in immunoreactivity recovery, oxidative stress and endothelial dysfunction elimination at chronic rhinosinusitis associated with comorbidity with immunocomprometation //European science review. – 2016. – №. 1-2. – C. 16-20.
2. Amonov S. E., Abdukayumov A. A., Sultanova D. THE CONDITION OF MUCOUS MEMBRANES OF NOSE AND PARANASAL SINUSES IN PATIENTS WITH CHRONIC KIDNEY DISEASE-AN EXPERIMENTAL MODEL //Folia Otorhinolaryngologiae et Pathologiae Respiratoriae. – 2012. – T. 18. – №. 2. – C. 10-11.
3. Cho S.W. Classification of chronic rhinosinusitis according to a nasal polyp and tissue eosinophilia: limitation of current classification system for Asian population / S.W. Cho, D.W. Kim, J.W. Kim, et al. // Asia Pac Allergy. – 2017. – Vol. 7, №3. – P. 121–130.
4. Dilmuratovna S. D. The role of immunologic values in the pathogenesis of chronic rhinosinusitis in children //European science review. – 2014. – №. 3-4. – C. 64-66.
5. Ergashevich A. S. et al. CLINICAL COURSE OF ALLERGIC RHINITIS COMBINED WITH ADENOID VEGETATION AND RHINOSINUSITIS IN CHILDREN //JOURNAL OF BIOMEDICINE AND PRACTICE. – 2023. – T. 8. – №. 2.
6. Karabaev H. E. et al. Determination of microorganisms markers by the method GC-MS and efficacy evaluation of rhinosinusitis //Central Asian Journal of Medical and Natural Science. – 2022. – T. 3. – №. 4. – C. 384-393.
7. Mamatova S. R. et al. DETERMINATION OF MICROORGANISMS MARKERS BY THE METHOD GC-MS AND EFFICACY EVALUATION of RHINOSINUSITIS //Science and innovation in the education system. – 2023. – T. 2. – №. 2. – C. 13-15.

8. Sharp, H.R. Major complications and consent prior to endoscopic sinus surgery / H.R. Sharp, L. Crutchfield, J.M. Rowe-Jones, D.B. Mitchell // Clin. Otolaryngol. -2017. -Vol.26. - P.33-38.

9. Shavkatovna K. S., Nabieva S. S. NEUROPHYSIOLOGICAL FEATURES IN NEUROLOGICAL COMPLICATIONS IN CHILDREN WITH CHRONIC KIDNEY DISEASE //FORCIPE. – 2022. – T. 5. – №. S2. – C. 441.

10. Sultanovà D. D. MORPHOLOGICAL CHARACTERISTICS MUCOSAL POLYPS ON THE BACKGROUND RHINOSINUSITIS //Central Asian Journal of Pediatrics. – 2019. – T. 2. – №. 3. – C. 38-43.