




TASHKENT MEDICAL ACADEMY

100 TMA  
ANNIVERSARY



# Journal of Educational and Scientific Medicine



**Issue 1 | 2024**



OAK.UZ  
Google Scholar

Science Education Commission of the Cabinet  
Ministry of the Republic of Uzbekistan

**ISSN: 2181-3175**

## Reconstructive Surgery for Diabetic Foot Syndrome

K.J. Matmurotov,<sup>1</sup> B.A. Ruzmetov, T.Sh. Atajanov

### ABSTRACT

**Background.** The study aims to improve the results of surgical treatment of patients with neuroischemic foot ulcers on the background of diabetic foot syndrome by improving reconstructive operations.

**Materials and methods.** In this work, the results of the surgical treatment of 27 patients in 2021-2022 who received inpatient treatment with chronic neuroischemic foot processes against the background of diabetic foot syndrome in the department of purulent surgery and surgical complications of diabetes mellitus at the multidisciplinary clinic of the Tashkent Medical Academy were analyzed.

**Results.** Using the developed method of reconstructive foot surgery in patients with a neuroischemic wound on the background of diabetes mellitus, we were able to obtain excellent results in 96.3% of cases with primary healing of the postoperative wound. Only one patient (3.7%) showed signs of suppuration of the postoperative wound and this was due to the patient's incompetence.

**Conclusions.** Comprehensive information about the condition of foot tissues in chronic neuroischemic ulcers against the background of diabetic foot syndrome allows you to choose an adequate treatment strategy using minimally invasive and surgical interventions on the foot.

**Keywords:** diabetes mellitus; diabetic foot syndrome; neuroischemic wound; gangrene.

### INTRODUCTION

One of the most severe complications of diabetes mellitus (DM) leading to surgical operations is diabetic foot syndrome (DFS). Diabetic foot syndrome manifests itself in the form of the development of widespread purulent-necrotic lesions in the lower extremities, which develop in 35-60% of DM patients [13].

Diabetic neuroarthropathy (DNOAP, Charcot's foot, Charcot's joint) is a rare but extremely severe complication of diabetes mellitus, with inadequate treatment leading to irreversible disability [1,4].

This complication can be called one of the most mysterious forms of diabetic foot syndrome since it is extremely difficult to predict the development of DNOAP and identify risk groups among patients with diabetes mellitus [15].

Doctors of different specialities – surgeons, endocrinologists, orthopedists - meet with this complication of diabetes, but it is not always recognized in time. Pathogenetically, with the appearance of signs of diabetic neuropathy in patients, it is possible to detect a violation of arterial blood flow in the lower extremities [2]

<sup>1</sup> **Author for correspondence:** PhD, DSc, MD, Associate Professor of the Department of General and Pediatric Surgery-1 of Tashkent Medical Academy, Tashkent, Uzbekistan. E-mail: [mqj\\_80@mail.ru](mailto:mqj_80@mail.ru)

The prevalence of this complication among patients with diabetes mellitus is less than 1% [11], although in the literature it is possible to find information about various manifestations of DNOAP in 18-25% of people with diabetes more than 20 years [4,17].

This inconsistency of information is obviously due to differences in the examination methodology and different criteria for the diagnosis of neuroosteoarthropathy.

An untimely diagnosis of the acute stage of DOAP and, accordingly, late treatment lead to pronounced changes in the bones and joints of the foot and the formation of irreversible deformities [18].

In the future, due to the bone protrusions that have arisen and changes in the biomechanics of the foot, high-pressure zones are formed with the crushing of the underlying soft tissues and, as a result, long-term non-healing, recurrent ulcerative defects. The addition of signs of ischemia complicates the problem before the practising surgeon gets the expected result of treatment [14,21].

Infection of wound defects, the development of phlegmon, osteomyelitis of bones and destructive osteoarthritis significantly increase the risk of high amputations in neuroischemic ulcers [20].

Data on the frequency of purulent complications, amputations, as well as long-term results of reconstructive surgical interventions in this category of patients are contradictory [16,22].

In connection with the above, the following clinical observation of a patient with a neuroischemic ulcer of the plantar surface against a background of severe ischemia, who preserved the supporting function of the foot with the help of an individually developed surgical treatment strategy consisting of repeated surgical treatments (for phlegmon of the foot and purulent lesions of bones and joints) and plastic reconstruction of the foot, is interesting.

In this regard, this study aimed to improve the results of surgical treatment of patients with neuroischemic foot ulcers against the background of diabetic foot syndrome (DFS) by improving reconstructive operations.

## MATERIAL AND METHODS

In this paper, the results of the surgical treatment of 27 patients in 2021-2022 who received inpatient treatment with chronic neuroischemic foot processes against the background of DFS in the department of purulent surgery and surgical complications of diabetes mellitus at the multidisciplinary clinic of the Tashkent Medical Academy were analyzed.

The average duration of diabetes mellitus was  $12.3 \pm 4.7$  years. The age of the patients ranged from 41 to 68 years (on average  $53.6 \pm 4.9$  years). Among the patients, there were 18 (66.7%) men and 9 (33.3%) women. The neuroischemic form of diabetic foot syndrome has been diagnosed in all cases. The duration of inpatient treatment of patients averaged 5-7 days. Before admission to the clinic, the duration of neuroischemic foot ulcers in patients was from 4 months to 3 years.

15 (55.6%) patients had signs of coronary heart disease (CHD). In 2 (7.4%) cases, there were signs of transient disorders of cerebral circulation in the anamnesis. Arterial hypertension was noted in 11 (40.7%) patients. All patients were consulted and correction of disorders from concomitant diseases was carried out.

The instrumental method for assessing the state of macrocirculation was ultrasound duplex scanning of the lower extremities performed on the ultrasound duplex system Medison-X6 (Samsung, Germany) according to the standard method with a linear sensor with a frequency of 7-15 MHz. Using ultrasound, the ankle-shoulder index (ASI) was also determined.

The final diagnostic method was multispiral computed tomography (MSCT) arteries of the lower extremities. After receiving information about the state of the peripheral arterial bed, all patients underwent restoration of blood flow by balloon angioplasty. Statistical data processing was performed using applied computer programs for statistical processing of the DBASE and STAT4 databases.

In patients after endovascular revascularization against the background of improved arterial circulation, we applied an improved method of foot reconstruction in chronic neuroischemic ulcers in patients with diabetic foot syndrome, by filling the bed with myoplasty (closing the operating bed) after resection of bones or joints and with the removal of fragmented bone tissue particles, taking into account the preservation of the arterial network of the foot (RUz№ IAP 2019 0202 from 13.05.2019 "A method of foot reconstruction in neuroischemic ulcers against the background of diabetic foot syndrome").

The proposed operation is performed under local conduction anaesthesia. At the first stage of foot reconstruction, access to the pathological focus from the back surface is carried out to prevent arterial network disorders (damage to solus plantar arteries). At the second stage, the metatarsal head is resected with the removal of fragmented particles. The final stage of the operation



includes myoplasty with m. flexor digitorum minimi brevis on the feeding leg with filling of the resected bed of bone tissue.

## RESULTS

Using the developed method of reconstructive foot surgery in patients with a neuroischemic wound on the background of diabetes mellitus, we were able to obtain excellent results in 96.3% of cases with primary healing of the postoperative wound. Only one patient (3.7%) showed signs of suppuration of the postoperative wound and this was due to the patient's incompetence, since despite the recommendations for unloading the limb after discharge from the clinic, he actively moved with the help of the affected limb. The patient was re-hospitalized and underwent a course of antibacterial and infusion therapy along with repeated rehabilitation. As a result, the postoperative wound healed by secondary tension.

In other cases, the sutures were removed after control radiography of the foot, and at the same time, we focused on the appearance of primary calluses and consolidation in the resected foot bone. After the operation, patients were advised to wear orthopaedic shoes. At the same time, in most cases, we applied Total Contact Cast (TCC) to patients to prevent possible further complications.

## CLINICAL OBSERVATION

Patient K.N., born in 1954, medical history № 378/27, 05.01.2021, turned to our department with complaints of a purulent non-healing wound of the plantar surface of the left foot, an increase in body temperature, pain and redness of the foot.

For the first time, a purulent wound appeared 2.5 years ago and the patient repeatedly received inpatient treatment in surgical departments at the place of residence. Suffers from diabetes mellitus.

The purulent discharge has been increasing for the last 3 days and the pain in the foot has intensified. Locally: the lower extremities are asymmetrical, due to swelling of the left foot.

On the plantar surface of the left foot, there is a purulent-necrotic wound measuring 3.0 x 4.0 cm.

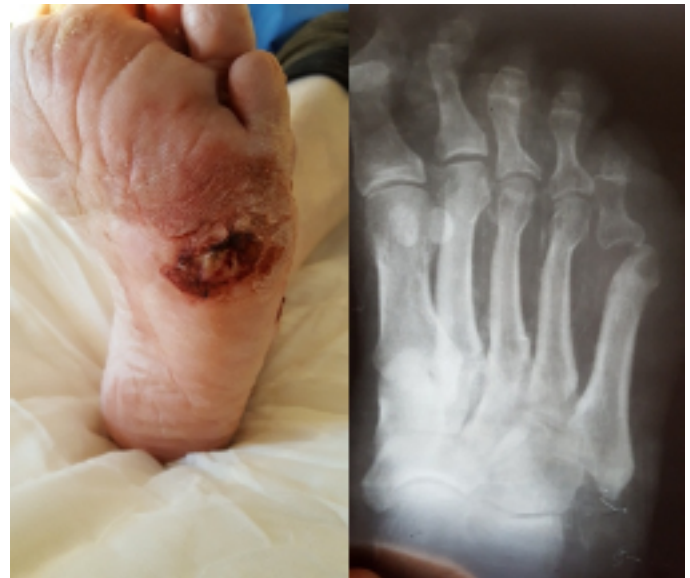An abundant purulent discharge with a fetid odour is released from the wound.

There is pronounced infiltration and soreness in the area of the plantar and back surfaces of the foot.

There is no pulsation in the peripheral arteries.

A contrast examination of the vessels of the lower extremities was recommended to the patient.

The patient was found to have signs of a neuroischemic ulcer of the plantar surface of the left foot, complicated by phlegmon, against the background of critical foot ischemia (see Fig.1).



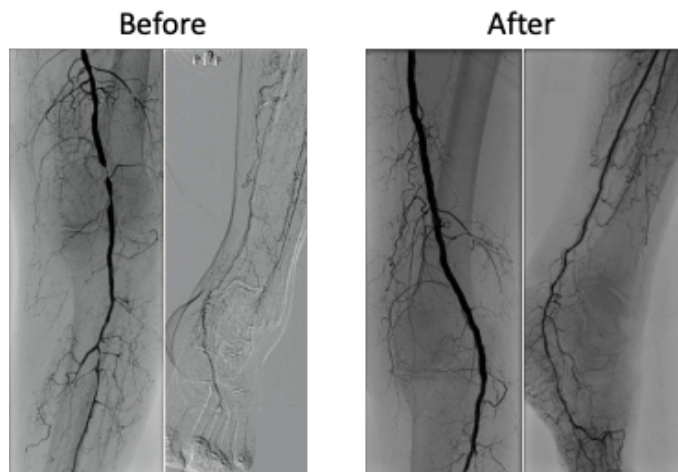
**Fig.1. Neuroischemic ulcer of the plantar surface of the foot and subluxation of the head of the V-metatarsal bone with destruction.**

Foot condition according to WIFI classification: W-2, I-1, FI-2. The risk is high (8 points). In this regard, against the background of normalization of indicators of biochemical blood tests, it was decided to do MSCT of the arteries of the lower extremities to the patient.

At the same time, signs of segmental occlusion of the a. poplitea (PA) and total occlusion of the tibial arteries on the left were revealed. On the foot, the blood flow is collateral due to contrast through the a. tibialis posterior (ATP), but the a.dorsalis pedis (DPA) is not contrasted. After clarifying the diagnosis and identifying the segment of arterial lesion, on the 2nd day after admission, balloon angioplasty of a. poplitea (PA) and a. tibialis posterior (TPA) on the left was performed with technical difficulties. At the same time, the lumen of the a. poplitea (PA) was completely restored without residual stenosis, the posterior tibial artery was restored to the arterial arch of the foot (see Fig. 2).

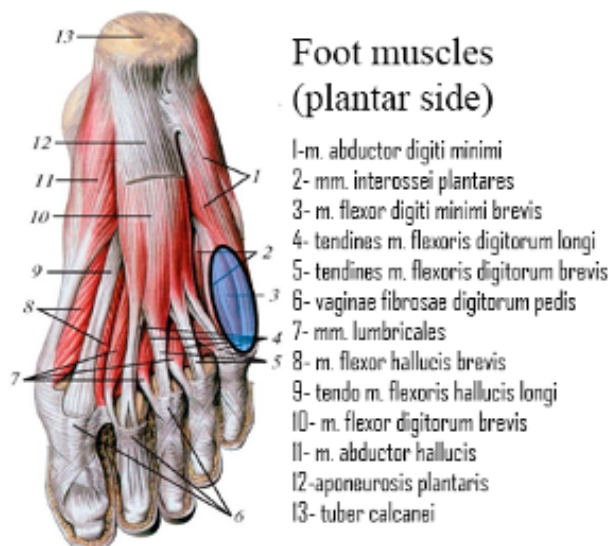
The restoration of a. tibialis anterior (ATA) and a. peronea (PerA) was not successful, and despite this, the main blood flow on the foot was obtained due to a. tibialis posterior (TPA). Against the background of improvement of local arterial blood flow, the patient underwent reconstruction of the foot with the elimination of the pathological focus. In this case, surgical tactics on

the foot were performed according to the foot plastic surgery technique developed by us.



**Fig.2. Segmental occlusion of the a. poplitea (PA), total occlusion of the lower leg arteries before and after BAP.**

At the same time, the first stage we performed a skin incision on the back of the foot, so as not to damage the lateral plantar artery. The second stage of the operation included resection of the destructively altered head of the metatarsal bone and the proximal phalanx of the V-toe of the left foot with the rehabilitation of the pathological focus.

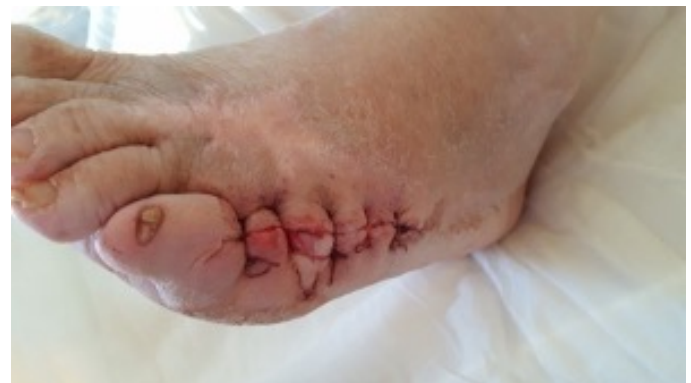

**Fig.3. Localization of the pathological focus and muscle for plastic surgery.**

The third stage of the operation was muscle plastic surgery of the residual cavity of the bed of the resected metatarsophalangeal joint with the help of a short flexor muscle of the little finger of the foot. This developed surgical tactic creates an optimal condition for the operating surgeon to preserve the integrity of the plantar lateral arterial network of the foot and prevent possible postoperative complications (see Fig. 3).

Using this treatment strategy, we try not only to preserve the physiological state of the foot, but also give psychological stability in terms of improving the quality of life of patients. The result of treatment is directly affected by the patient's compliance, which in most cases is the cause of subsequent possible complications.

After reconstructive plastic surgery of the foot, the patient underwent short-term immobilization (for 3 days), which is necessary for the engraftment of the muscle flap and the prevention of possible hematomas in the area of the resected joint bed. On the 7th day, the patient was discharged home in a satisfactory condition for outpatient observation (see Fig.4.).



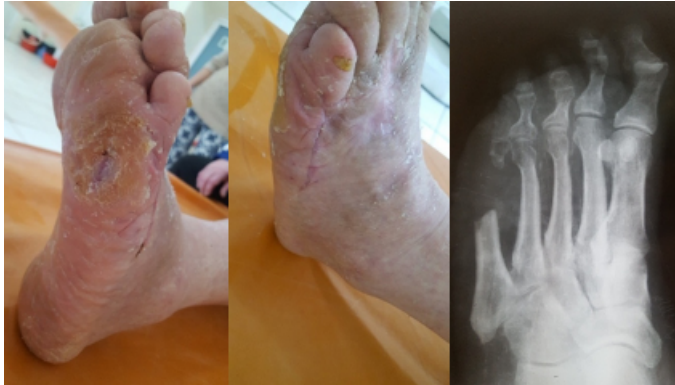**Fig.4. View of the foot after reconstructive surgery.**

The patient had a smooth postoperative period, the wound healed by primary tension and on the 21st day after the operation, there were signs of the appearance of a primary bone callus on the radiograph without signs of destruction. The patient actively moves and regularly uses orthopaedic shoes (see Fig.5).

## DISCUSSION

The analysis of the results of treatment of patients with neuroischemic foot ulcer on the background of diabetic foot syndrome showed that with the correct definition of the treatment strategy in 96.3% of cases, it is possible to ensure a smooth course of the wound process, with primary tension of the

postoperative wound. These results were achieved due to the correct selection of operational equipment according to the original method developed by us [3,8].



**Fig.5. The view of the foot on the 17th day after the reconstruction of the foot.**

In our opinion, it is possible to choose an adequate technique of surgical intervention on the foot in the presence of chronic neuroischemic ulcers only by conducting a comprehensive examination of the patient, taking into account several objective data. When determining the treatment strategy, it is necessary to consider the general condition of the patient, the degree of local tissue damage on the foot and the compensation of limb ischemia [6,9].

The issue of the need for revascularization operations of the lower limb in patients with trophic ulcers on the foot should be resolved only after evaluating the possibility of endovascular intervention, the successful implementation of which reduces the level of postoperative complications and high amputations of the lower extremities. The question of the possibility of direct revascularization of the limb should be resolved before surgery, based on the data of detailed duplex scanning and MSCT of the arteries of the lower extremities. At the same time, to determine the volume of the operation, an objective assessment of the degree of violation of peripheral arterial blood flow is required based on the data of the above-mentioned research methods [7,10].

When preparing patients for a complex of therapeutic measures, it is important to pay special attention to the correction of rheological and coagulation properties of blood, normalization of the functional state of cardiac activity, as well as to convey to the patient and relatives important information about further rehabilitation tactics, in particular wearing orthopedic shoes to prevent repeated purulent complications of the foot.

## CONCLUSION

1. Complete information about the condition of the foot tissues in chronic neuroischemic ulcers against the background of diabetic foot syndrome allows to choose an adequate treatment strategy using minimally invasive and surgical interventions on the foot. The optimal intervention in case of damage to the plantar surface is the use of an original method of foot reconstruction, which in 96.3% of cases will get an excellent result of treatment.

2. Patients with purulent-necrotic process in the foot area with diabetes mellitus are shown an adequate comprehensive diagnosis to determine individual treatment tactics. Determination of the level of occlusive-stenotic lesions of the peripheral arteries of the lower extremities, if indicated, its correction by endovascular means plays an important role in achieving the expected result in purulent-necrotic lesions of the feet in patients with diabetes mellitus.

**Acknowledgements** – The authors would like to thank the multidisciplinary clinic of the Tashkent Medical Academy for providing an opportunity to conduct this study.

**Conflict of Interest** – The authors state that they have no conflict of interest.

**Ethical Statement** - to publish these results we obtain the Ethics Committee of the Tashkent Medical Academy. All patients were informed about the research process. All of them signed the relevant letter of consent.

**Data Availability Statement** - Data supporting the results of this study are available at the request of the respective author. The data is not publicly available because it contains information that could compromise the privacy of study participants.

**Financing** – independent

## REFERENCES:

1. Babadjanov B.D., Matmurotov K.J. "Method of foot reconstruction in neuroischemic ulcers against the background of diabetic foot syndrome" (patent of the Republic of Uzbekistan No. IAP to 2019 0202 dated 13.05.2019)
2. Babadjanov B.D., Matmurotov K.J., Otajonov J.Kh. The use of minimally invasive methods of treatment in patients with diabetic gangrene of the lower extremities // Med. journal. Uzbekistan. – 2019. – No. 1. – pp. 45-49.
3. Babadjanov B.D., Matmurotov K.J., Sattarov I.S., Ruzmetov B.A., Atajonov T.Sh. Combined Endovascular Interventions for Lesions of the Peripheral Arteries of the

Lower Extremities on the Background of Diabetes Mellitus // *Journal of Biomedicine and Practice*. Tashkent -2023. Volume 8, ISSUE 3. –P.303-309.

4. Eroshkin I.A. Long-term results of treatment of patients with purulent-necrotic forms of diabetic foot syndrome depending on the use of revascularization methods // *News of surgery*. - 2013. – Vol. 21, No. 4. – pp. 62-70.

5. Kayumova, D., Korikhonov, D., Shukurov, F., Khaydarov, F., Gulmanov, I., Marupov, I., Kurbanov, O., Sattarov, O., Azizova, P., Ruzmatov, P., & Sharipov, Y. (2023). Ways to Improve the Results of Diagnosis and Treatment of Severe Forms of Purulent-Inflammatory Diseases of Soft Tissues Complicated by Sepsis. // *Journal Of Education And Scientific Medicine*, 1(4), P.35-42. Retrieved from <https://mail.journals.tma.uz/index.php/jesm/article/view/594>

6. Matmurotov K.Zh., Ruzmatov P.Yu., Ruzmetov B.A., Rahimov D.D., Saitov D.N. Minimally Invasive Endovascular Methods of Treatment of Patients With Surgical Complications of Diabetic Foot Syndrome // *Problems of Biology and Medicine*. 2022, № 6.1 (141) <https://doi.org/10.38096/2181-5674.2022.6.1> -P.244-247.

7. Matmurotov K.J., Ruzmatov P.Yu., Atajanov T.Sh., Ruzmetov B.A., Yakubov I.Yu. The Significance of Transcutaneous Oximetry in Determining the Tactics of Treatment of Distal Foot Gangrene in Patients with Diabetes Mellitus // *American Journal of Medicine and Medical Sciences* 2023, 13(2): P.87-90. DOI: 10.5923/j.ajmms.20231302.12

8. Matmurotov K.Zh., Ruzmatov P.Yu., Ruzmetov B.A., Saitov D.N. Differentiated Strategy for Performing Reconstructive Plastic Surgery for Diabetic Foot Syndrome // *Texas Journal of Medical Science*. <https://zien-journals.com> Volume 21. 07-06-2023. P.23-30.

9. Matmurotov K.J., Sattarov I.S., Ruzmatov P.Yu., Rahimov D.D., Yakubov I.Yu. Leg Amputations: A Differentiated Approach to Performance Depending on the Lesion of the Arterial Basin // *American Journal of Medicine and Medical Sciences* 2023, 13(2): 81-86 DOI: 10.5923/j.ajmms.20231302.11

10. Matmurotov K.J., Ruzmatov P.Yu., Sattarov I.S., Ruzmetov B.A., Yakubov I.Yu. Differentiated Strategy of Performing Reconstructive Operations in Patients With Diabetic Foot Syndrome // *Problems of Biology and Medicine*. 2023, № 5 (148) <https://doi.org/10.38096/2181-5674.2023.5> -P.145-150.

11. Nuzova O.B., Studenikin A.V., Stadnikov A.A. New methods of treatment of patients with various forms of diabetic foot syndrome. // "High amputations of the lower extremities in children and adults". Collection of scientific papers of the international scientific and practical conference. Moscow. -2019. – pp. 96-98.

12. Okhunov A., Kayumova D., Korikhonov D., Shukurov F., et al. Diagnosis and Treatment of Necrotizing Soft Tissue Infection Complicated By Sepsis. // *Eur. Chem. Bull.* 2023,12(Special Issue 7), 7318-30.

13. Pokrovsky A.V., Kazakov Yu.I., Lukin B.I. Critical ischemia of the lower extremities. - Moscow: RIC-TSMU, 2018. – 225 p.

14. Udovichenko O.V., Grekova N.M. Diabetic foot. Guide for doctors. – M.: Practical medicine, 2010. – 272 p.

15. Yanushko V.A., Isachkin D.V. Critical ischemia of the lower extremities. Minsk.:Businessofset. – 2014. 231 p.

16. Armstrong E.J, Bishu K, Waldo S.W. Endovascular Treatment of Infrapopliteal Peripheral Artery Disease. // *Curr Cardiol Rep.* 2016;18(4):38. <https://doi.org/10.1007/s11886-016-0708-y>.

17. Diabetic Microangiopathy Is an Independent Predictor of Incident Diabetic Foot Ulcer / M. Tomita, Y. Kabeya, M. Okisugi [et al.] // *J. Diabetes Res.* – 2016. – Vol. 2018. – 5938540.

18. Graziani L, Silvestro A, Bertone V, et al. Vascular involvement in diabetic subjects with ischemic foot ulcer: a new morphologic categorization of disease severity // *Eur J Vasc Endovasc Surg.* 2007;33:4:453-460. <https://doi.org/10.1016/j.ejvs.2006.11.022>

19. Morbi A.H., Shearman C.P. Topical Negative Pressure Therapy for Diabetic Foot Ulcers: Where Is the Evidence // *Int. J. Low Extrem. Wounds.* – 2017. – Vol. 15 (1). – P. 96.

20. Neuropathic osteoarthropathy with and without superimposed osteomyelitis in patients with diabetic foot / A. Leone, V.N. Cassar-Pullicino, A. Semprini [et al.] // *Skeletal Radiol.* – 2016. – Feb 17.

21. Preoperative medical treatment in patients undergoing diabetic foot surgery with a Wagner Grade-3 or higher ulcer: a retrospective analysis of 52 patients / M. Korkmaz [et al.] // *Diabet Foot Ankle.* – 2012. – N 3. – P. 10.

22. Xu Z., Ran X. Diabetic foot care in China: challenges and strategy // *Lancet Diabetes Endocrinol.* – 2016. – Vol. 4 (4). – P. 297298.



## DIABETIK PANJA SINDROMIDA REKON- STRUKTIV OPERATSIYALAR

Matmurotov Q.J.,<sup>1</sup> Ruzmetov B.A.,<sup>2</sup> Atajanov T.Sh.<sup>1</sup>

<sup>1</sup>Toshkent tibbiyot akademiyasi

<sup>2</sup>Toshkent tibbiyot akademiyasi Urganch filiali

### ABSTRAKT

**Dolzarbligi.** Diabetik panja sindromi (DPS) fonida neyroishemik oyoq yarasi bo'lgan bemorlarni rekonstruktiv operatsiyalarni takomillashtirish orqali jarrohlik davolash natijalarini yaxshilash.

**Materiallar va usullar.** Mazkur ishda 2021-2022 yillar davomida Toshkent tibbiyot akademiyasi ko'p tarmoqli klinikasi yiringli jarrohlik va qandli diabetning jarrohlik asoratlari bo'limida DPS fonida oyoqning surunkali neyroishemik jarayonlari bilan statsionar davolangan 27 nafar bemorlarni jarrohlik yo'li bilan davolash natijalari tahlil qilindi.

**Natijalar.** Ishlab chiqilgan oyoq panjasi rekonstruktiv operatsiyasini qo'llash yordamida qandli diabet fonida neyroishemik yarasi bo'lgan bemorlarda yaxshi natijalarga erishdik, operatsiyadan keyingi jarohatning birlamchi bitishi 96,3% hollarda kuzatildi. Faqat bitta bemorda (3,7%) operatsiyadan keyingi yara yiringlash belgilari kuzatilgan va bu bemorning talablarga rioya qilmasligi bilan bog'liq.

**Xulosalar.** Shunday qilib, qandli diabet fonida oyoq panjasi sohasida yiringli-nekrotik jarayon bilan og'rigan bemorlarga individual davolash taktikasini aniqlash uchun etarli kompleks diagnostik tekshiruvlar o'tkazish lozim.

**Kalit so'zlar:** qandli diabet, diabetik panja sindromi, neyroishemik yara, gangrena.

## РЕКОНСТРУКТИВНЫЕ ОПЕРАЦИИ ПРИ СИНДРОМЕ ДИАБЕТИЧЕСКОЙ СТОПЫ

Матмуротов К.Ж.,<sup>1</sup> Рузметов Б.А.,<sup>2</sup> Атажанов Т.Ш.<sup>1</sup>

<sup>1</sup>Ташкентская медицинская академия

<sup>2</sup>Ургенчский филиал Ташкентской медицинской академии

### АБСТРАКТ

**Актуальность.** Целью исследования явилось улучшение результатов хирургического лечения больных нейроишемическими язвами стоп на фоне синдрома диабетической стопы (СДС) с помощью усовершенствованием реконструктивных операций.

**Материалы и методы.** В данной работе было проанализировано результаты хирургического лечения 27 больных за 2021-2022гг. получивших стационарное лечение с хроническими нейроишемическими процессами стопы на фоне СДС в отделении гнойной хирургии и хирургических осложнений сахарного диабета при многопрофильной клинике Ташкентской медицинской академии.

**Результаты.** С помощью разработанного способа реконструктивной операции стопы у пациентов с нейроишемической раной на фоне сахарного диабета нам удалось получить отличные результаты в 96,3% случаях с первичным заживлением послеоперационной раны. Только у одного пациента (3,7%) наблюдались признаки нагноения послеоперационной раны и это было связано с некомпетентностью больного.

**Заключения.** Полноценная информация о состоянии тканей стопы при хронических нейроишемических язвах на фоне синдрома диабетической стопы позволяет выбрать адекватную стратегию лечения с применением малоинвазивных и хирургических вмешательств на стопе.

**Ключевые слова:** сахарный диабет, синдром диабетической стопы, нейроишемическая рана, гангрена.